

Vesiculobullous Diseases

Epidermolysis Bullosa

Etiology

- A diverse group of predominantly cutaneous, but also mucosal, mechanobullous diseases
- Inherited form: autosomal dominant or recessive patterns may occur
- Acquired form (acquisita): autoimmune from autoantibodies (immunoglobulin G [IgG]) to type VII collagen deposited within the basement membrane zone and upper dermis or lamina propria

Clinical Presentation

- Variable, depending upon the specific form of many subtypes recognized
- Mucosal lesions range in severity from mild to debilitating, depending on subtype:
 - Inherited forms have wide range of oral mucosal involvement, with most severe form (autosomal recessive, dermolytic) also demonstrating enamel hypoplasia and caries
 - Acquisita form with mucous membrane pemphigoid variant shows oral and conjunctival erosions/blisters
- Mucosal involvement absent in several variants
- Scarring and stricture formation common in severe recessive forms
- Mucosa is often friable, but it may be severely blistered, eroded, or ulcerated.
- Loss of oral anatomic landmarks may follow severe scarring (eg, tongue mucosa may become smooth and atrophic with episodes of blistering and scarring).
- Obliteration of vestibules, reduction of oral opening, ankyloglossia
- Scarring can be associated with atrophy and leukoplakia, with increased risk for squamous cell carcinoma development.

Microscopic Findings

- Bullae vary in location depending upon the form that is present:
 - Intraepithelial in nonscarring forms
 - At epithelial–connective tissue junction in dystrophic forms
 - Subepithelial/intradermal in scarring forms
- Ultrastructural findings are as follows:
 - Intraepithelial forms associated with defective cytokeratin groups
 - Junctional forms associated with defective anchoring filaments at hemidesmosomal sites (epithelial–connective tissue junction)
 - Dermal types demonstrate anchoring fibril or collagen destruction.

Diagnosis

- Distribution of lesions
- Family history
- Microscopic evaluation
- Ultrastructural evaluation
- Immunohistochemical evaluation of basement membrane zone using specific labeled antibodies as markers for site of blister formation

Differential Diagnosis

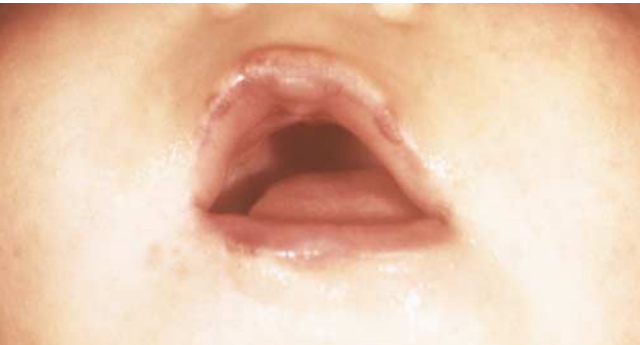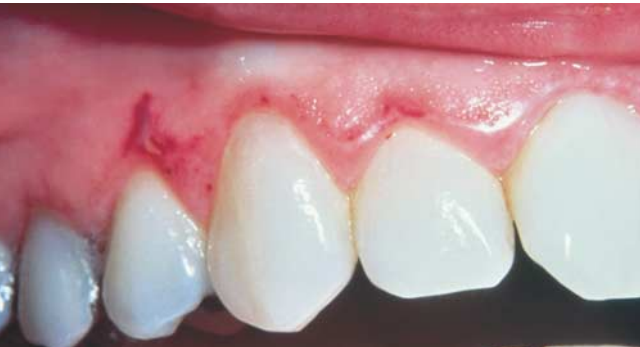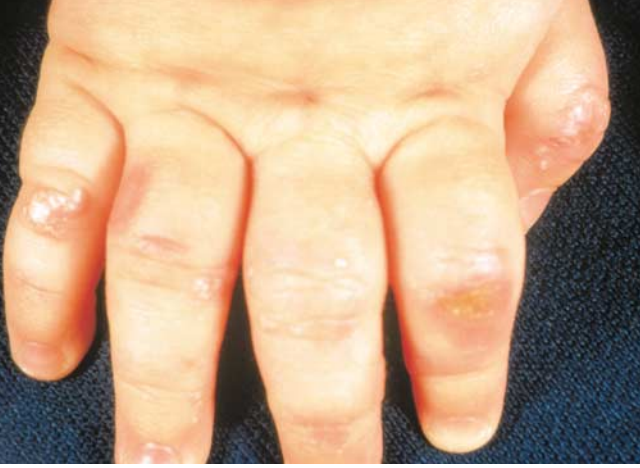- Varies with specific form
- Generally includes the following:
 - Bullous pemphigoid
 - Mucous membrane (cicatricial) pemphigoid
 - Erosive lichen planus
 - Dermatitis herpetiformis
 - Porphyria cutanea tarda
 - Erythema multiforme
 - Bullous impetigo
 - Kindler syndrome
 - Ritter's disease

Treatment

- Acquisita form:
 - Some recent success with colchicine and dapsone
 - Immunosuppressive agents including azathioprine, methotrexate, and cyclosporine may be effective
- Acquisita and inherited forms:
 - Avoidance of trauma
 - Dental prevention strategies including extra-soft brushes, daily topical fluoride applications, dietary counseling

Prognosis

- Widely variable depending on subtype



Erythema Multiforme

Etiology

- Many cases preceded by infection with herpes simplex; less often with *Mycoplasma pneumoniae* or other organisms
- May be related to drug consumption, including sulfonamides, other antibiotics, analgesics, phenolphthalein-containing laxatives, barbiturates
- Another trigger may be radiation therapy.
- Essentially an immunologically mediated reactive process, possibly related to circulating immune complexes

Clinical Presentation

- Acute onset of multiple, painful, shallow ulcers and erosions with irregular margins
- Early mucosal lesions are macular, erythematous, and occasionally bullous.
- May affect oral mucosa and skin synchronously or metachronously
- Lips most commonly affected with eroded, crusted, and hemorrhagic lesions (serosanguinous exudate) known as Stevens-Johnson syndrome when severe
- Predisposition for young adults
- As many as one-half of oral cases have associated erythematous to bullous skin lesions.
- Target or iris skin lesions may be noted over extremities.
- Genital and ocular lesions may occur.
- Usually self-limiting; 2- to 4-week course
- Recurrence is common.

Diagnosis

- Appearance
- Rapid onset
- Multiple site involvement in one-half of cases
- Biopsy results often helpful, but not always diagnostic

Differential Diagnosis

- Viral infection, in particular, acute herpetic gingivostomatitis (Note: Erythema multiforme rarely affects the gingiva.)

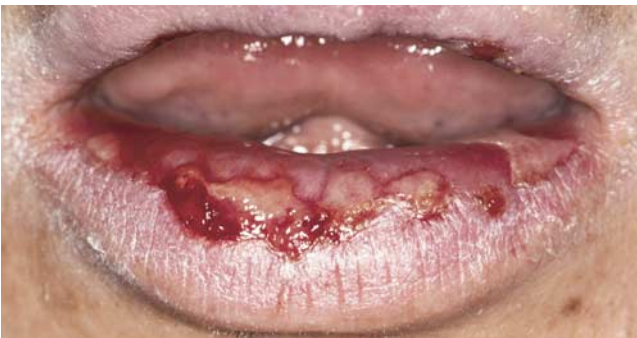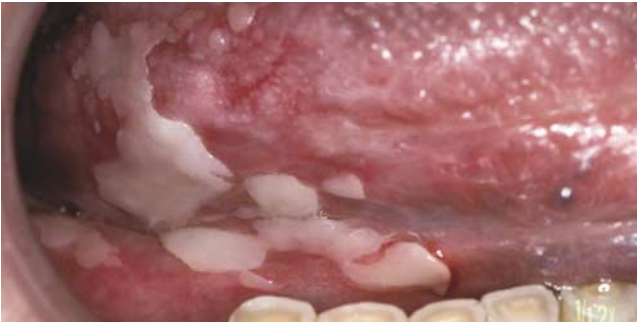- Pemphigus vulgaris
- Major aphthous ulcers
- Erosive lichen planus
- Mucous membrane (cicatricial) pemphigoid

Treatment

- Mild (minor) form: symptomatic/supportive treatment with adequate hydration, liquid diet, analgesics, topical corticosteroid agents
- Severe (major) form: systemic corticosteroids, parenteral fluid replacement, antipyretics
- If evidence of an antecedent viral infection or trigger exists, systemic antiviral drugs during the disease or as a prophylactic measure may help.
- See “Therapeutics” section for details.

Prognosis

- Generally excellent
- Recurrences common



Hand-Foot-and-Mouth Disease

Etiology

- A very common enterovirus infection (coxsackievirus A10 or A16), which may occur in mild epidemic proportion, chiefly in children
- Incubation period is short, usually less than 1 week

Clinical Presentation

- Oral mucosal lesions with focal herpes simplex–like appearance, usually involving nonkeratinized tissue (soft palate, floor of mouth, labial-buccal mucosa)
- Accompanying palmar, plantar, and digital lesions are deeply seated, vesicular, and erythematous
- Short course with mild symptoms

Diagnosis

- Concomitant oral and cutaneous lesions
- Skin lesions commonly involve hands and feet.
- Skin lesions may involve buttocks.
- Antibody-titer increase measured between acute and recovery phases

Differential Diagnosis

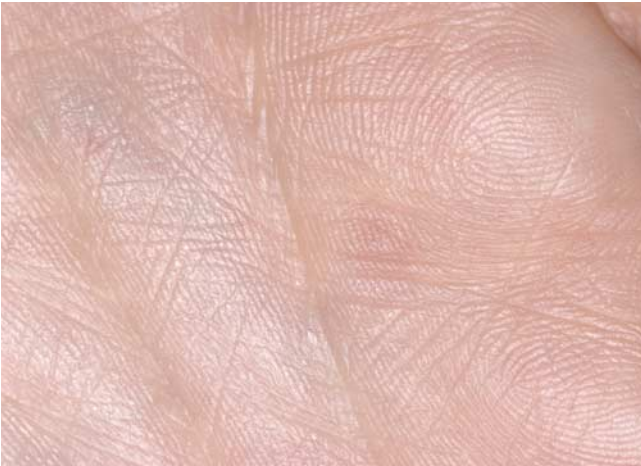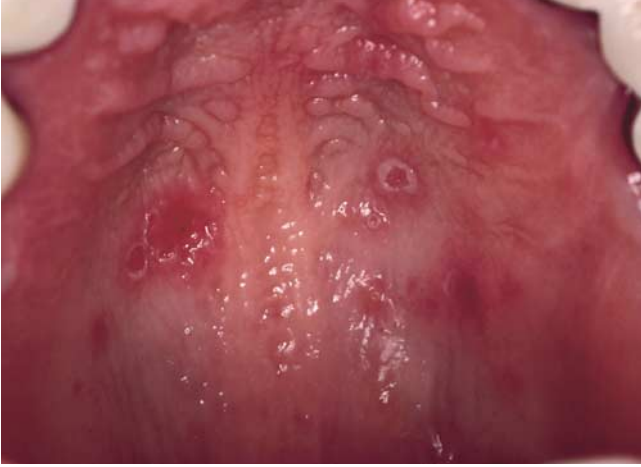- Herpangina
- Herpes simplex infection
- Acute lymphonodular pharyngitis

Treatment

- Symptomatic treatment only
- Patient should be cautioned against the use of aspirin to manage fever.

Prognosis

- Excellent
- Lifelong immunity, but it is strain specific



Herpangina

Etiology

- Most often by members of coxsackievirus group A (7, 9, 10, and 16) or group B (1–5)
- Occasionally due to echovirus 9 or 17

Clinical Presentation

- Incubation period of 5 to 9 days
- Acute onset
- Usually endemic in young children; usually occurs in summer
- Often subclinical
- Posterior oral cavity, tonsillar pillars involved
- Macular erythematous areas precede short-lived vesicular eruption, followed by superficial ulceration
- Accompanied by pharyngitis, dysphagia, fever, malaise, headache, lymphadenitis, and vomiting
- Self-limiting course, usually under 2 weeks

Diagnosis

- Other viral illnesses to be ruled out or separated
- Course, time of year, location of lesions, contact with known infected individual

Differential Diagnosis

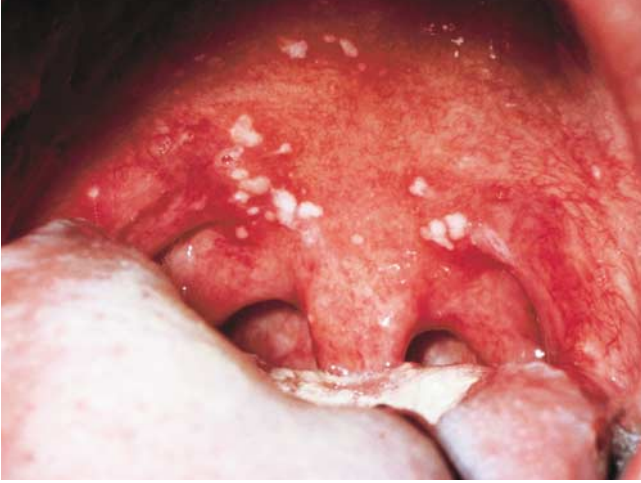- Hand-foot-and-mouth disease
- Varicella
- Acute herpetic gingivostomatitis

Treatment

- Soft diet
- Hydration
- Antipyretics
- Chlorhexidine rinses
- Compounded mouth rinses

Prognosis

- Excellent



Herpetic Stomatitis: Primary

Etiology

- Herpes simplex virus (HSV)
- Over 95% of oral primary herpes due to HSV-1
- Physical contact is mode of transmission

Clinical Presentation

- 88% of population experience subclinical infection or mild transient symptoms
- Most cases occur in those between 0.5 and 5 years of age.
- Incubation period of up to 2 weeks
- Abrupt onset in those with low or absent antibody to HSV-1
- Fever, anorexia, lymphadenopathy, headache, in addition to oral ulcers
- Coalescing, grouped, pinhead-sized vesicles that ulcerate
- Ulcers show a yellow, fibrinous base with an erythematous halo
- Both keratinized and nonkeratinized mucosa affected
- Gingival tissue with edema, intense erythema, pain, and tenderness
- Lips, perioral skin may be involved
- 7- to 14-day course

Diagnosis

- Usually by clinical presentation and pattern of involvement
- Cytology preparation to demonstrate multinucleate virus-infected giant epithelial cells
- Biopsy results of intact macular area show intraepithelial vesicles or early virus-induced epithelial (cytopathic) changes
- Viral culture or polymerase chain reaction (PCR) examination of blister fluid or scraping from base of erosion

Differential Diagnosis

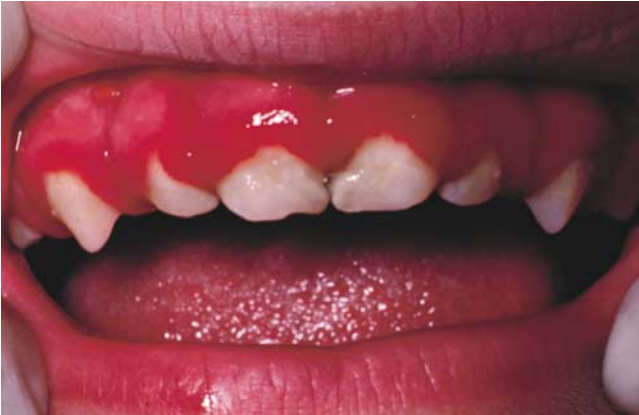- Herpangina
- Hand-foot-and-mouth disease
- Varicella
- Herpes zoster (shingles)
- Erythema multiforme (typically no gingival lesions)

Treatment

- Soft diet and hydration
- Antipyretics (avoid aspirin)
- Chlorhexidine rinses
- Systemic antiviral agents (acyclovir, valacyclovir) if early in course or in immunocompromised patients
- Compounded mouth rinse

Prognosis

- Excellent in immunocompetent host
- Remission/latent phase in nearly all those affected who have adequate antibody titers



Impetigo

Etiology

- Cutaneous bacterial infection: *Streptococcus* and *Staphylococcus* species
- Is spread through direct contact
- Highly contagious

Clinical Presentation

- Honey-colored, perioral crusts preceded by vesicles
- Flaccid bullae less common (bullous impetigo)

Diagnosis

- Clinical features
- Culture of organism (usually group A, β -hemolytic streptococci or group II *Staphylococcus aureus*)

Differential Diagnosis

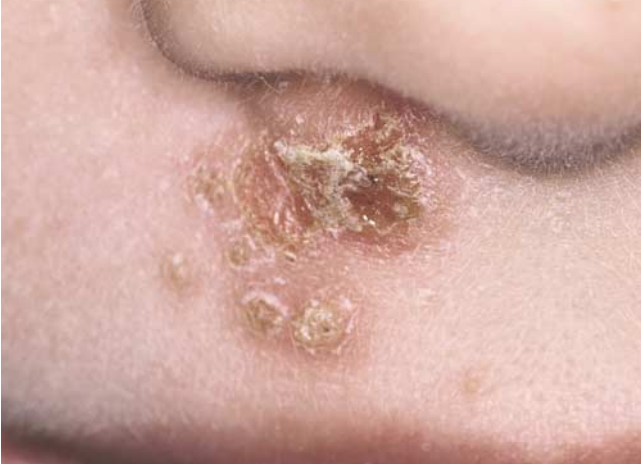- Herpes simplex (recurrent)
- Exfoliative cheilitis
- Drug eruptions
- Other vesiculobullous diseases

Treatment

- Topical antibiotics (mupirocin, clindamycin)
- Systemic antibiotics

Prognosis

- Excellent
- Rarely, poststreptococcal glomerulonephritis may develop.



Mucous Membrane Pemphigoid

Etiology

- Autoimmune; trigger unknown
- Autoantibodies directed against basement membrane zone antigens

Clinical Presentation

- Vesicles and bullae (short lived) followed by ulceration
- Multiple intraoral sites (occasionally gingiva only)
- Usually in older adults
- 2:1 female predilection
- Ocular lesions noted in one-third of cases
- Proclivity for scarring in ocular, laryngeal, nasopharyngeal, and oropharyngeal tissues

Microscopic Findings

- Subepithelial cleft formation
- Linear pattern IgG and complement 3 (C3) along basement membrane zone; less commonly IgA
- Direct immunofluorescence examination positive in 80% of cases
- Indirect immunofluorescence examination usually negative
- Immunoreactants deposited in lamina lucida in most patients

Diagnosis

- Biopsy
- Direct immunofluorescent examination

Differential Diagnosis

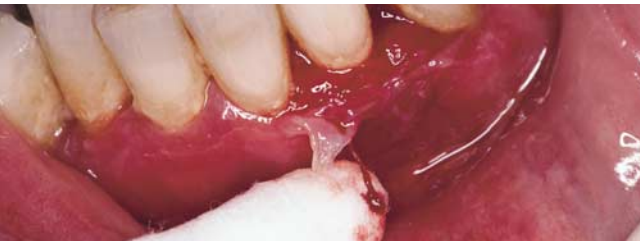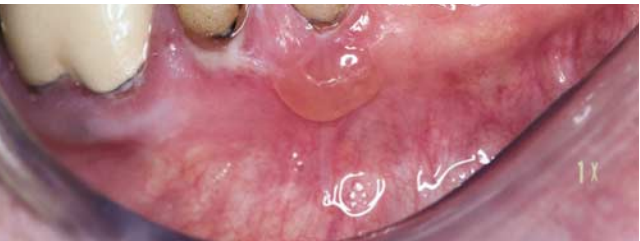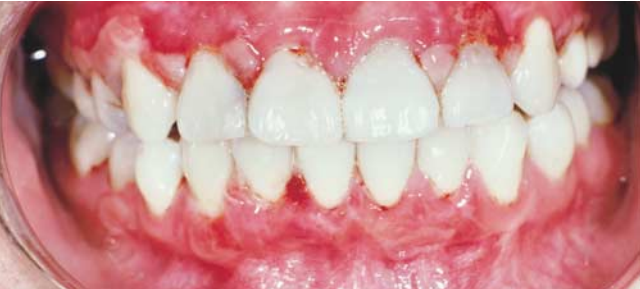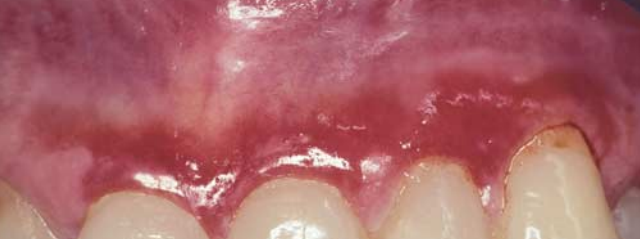
- Pemphigus vulgaris
- Erythema multiforme
- Erosive lichen planus
- Lupus erythematosus
- Epidermolysis bullosa acquisita

Treatment

- Topical corticosteroids
- Systemic prednisone, azathioprine, or cyclophosphamide
- Tetracycline/niacinamide
- Dapsone
- See “Therapeutics” section for details.

Prognosis

- Morbidity related to mucosal scarring (oropharyngeal, nasopharyngeal, laryngeal, ocular, genital)
- Management often difficult due to variable response to corticosteroids
- Management often requires multiple specialists working in concert (dental, dermatology, ophthalmology, otolaryngology)



Paraneoplastic Pemphigus

Etiology

- Autoimmune, triggered by malignant or benign tumors
- Autoantibodies directed against a variety of epidermal antigens including desmogleins 3 and 1, desmoplakins I and II, and other desmosomal antigens, as well as basement membrane zone antigens

Clinical Presentation

- Short-lived vesicles and bullae followed by erosion and ulceration; resembles oral pemphigus
- Multiple oral sites
- Severe hemorrhagic, crusted erosive cheilitis
- Painful lesions
- Cutaneous lesions are polymorphous; may resemble lichen planus, erythema multiforme, or bullous pemphigoid
- Underlying neoplasms such as non-Hodgkin's lymphoma, leukemia, thymoma, spindle cell neoplasms, Waldenström's macroglobulinemia, and Castleman's disease

Microscopic Findings

- Suprabasilar acantholysis, keratinocyte necrosis, and vacuolar interface inflammation
- Direct immunofluorescent testing is positive for epithelial cell surface deposition of IgG and C3 and a lichenoid tissue reaction interface deposition pattern
- Indirect immunofluorescent testing is positive for epithelial cell surface IgG antibodies
- Special testing with mouse and rat bladder, cardiac muscle, and liver may demonstrate paraneoplastic pemphigus antibodies that bind to simple columnar and transitional epithelia

Diagnosis

- Biopsy of skin or mucosa
- Direct immunofluorescent examination of skin or mucosa
- Indirect immunofluorescent examination of sera including special substrates

Differential Diagnosis

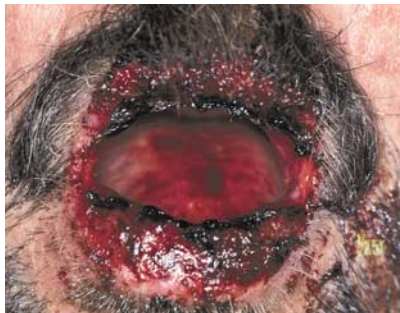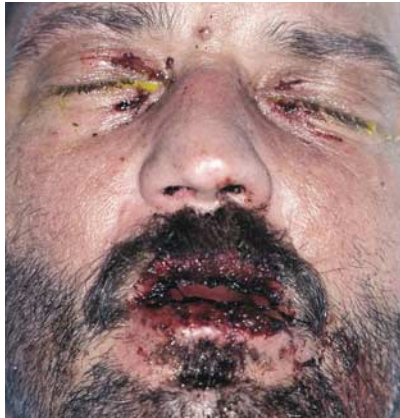- Pemphigus vulgaris
- Erythema multiforme
- Stevens-Johnson syndrome
- Mucous membrane (cicatricial) pemphigoid
- Erosive oral lichen planus

Treatment

- Identification of concurrent malignancy
- Immunosuppressive therapy

Prognosis

- Good with excision of benign neoplasms
- Grave, usually fatal, with malignancies
- Management is very challenging.



Pemphigus Vulgaris

Etiology

- An autoimmune disease where antibodies are directed toward the desmosome-related proteins desmoglein 3 or desmoglein 1
- A drug-induced form exists with less specificity in terms of immunologic features, clinical presentation, and histopathology

Clinical Presentation

- Over 50% of cases develop oral lesions as the initial manifestation
- Oral lesions develop in 70% of cases
- Painful, shallow irregular ulcers with friable adjacent mucosa
- Nonkeratinized sites (buccal, floor, ventral tongue) often are initial sites affected
- Lateral shearing force on uninvolved skin or mucosa can produce a surface slough or induce vesicle formation (Nikolsky sign)

Microscopic Findings

- Separation or clefting of suprabasal from basal layer of epithelium
- Intact basal layer of surface epithelium
- Vesicle forms at site of epithelial split
- Nonadherent spinous cells float in blister fluid (Tzanck cells)
- Direct immunofluorescence examination positive in all cases
- IgG localization to intercellular spaces of epithelium
- C3 localization to intercellular spaces in 80% of cases
- IgA localization to intercellular spaces in 30% of cases
- Indirect immunofluorescence examination positive in 80% of cases
- General correlation with severity of clinical disease

Diagnosis

- Clinical appearance
- Mucosal manifestations
- Direct/indirect immunofluorescent studies

Differential Diagnosis

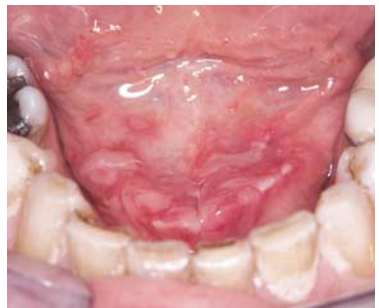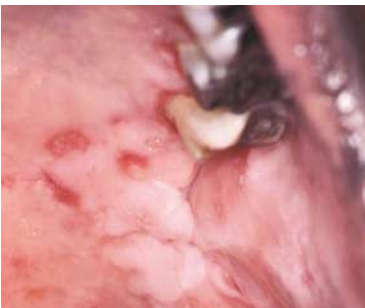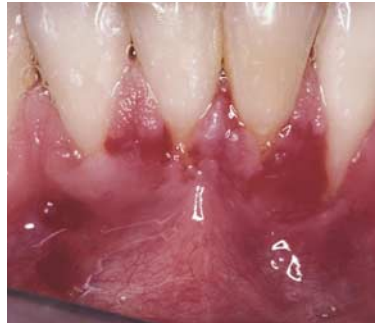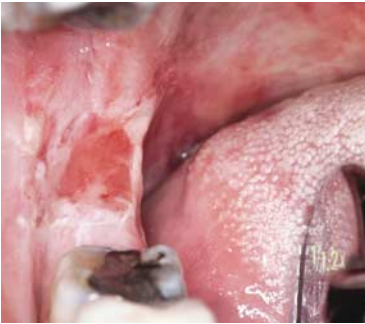- Mucous membrane (cicatricial) pemphigoid
- Erythema multiforme
- Erosive lichen planus
- Drug reaction
- Paraneoplastic pemphigus

Treatment

- Systemic immunosuppression
- Prednisone, azathioprine, mycophenolate mofetil, cyclophosphamide
- Plasmapheresis plus immunosuppression
- IVIg for some recalcitrant cases
- See “Therapeutics” section for details.

Prognosis

- Guarded
- Approximately a 5% mortality rate secondary to long-term systemic corticosteroid–related complications



Recurrent Herpetic Stomatitis: Secondary

Etiology

- Herpes simplex virus
- Reactivation of latent virus

Clinical Presentation

- Prodrome of tingling, burning, or pain at site of recurrence
- Multiple, grouped, fragile vesicles that ulcerate and coalesce
- Most common on vermilion border of lips or adjacent skin
- Intraoral recurrences characteristically on hard palate or attached gingiva (masticatory mucosa)
- In immunocompromised patients, lesions may occur in any oral site and are more severe (herpetic geometric glossitis).

Diagnosis

- Characteristic clinical presentation and history
- Viral culture or PCR examination of blister fluid or scraping from base of erosion
- Cytologic smear
- Direct immunofluorescence examination of smear

Differential Diagnosis

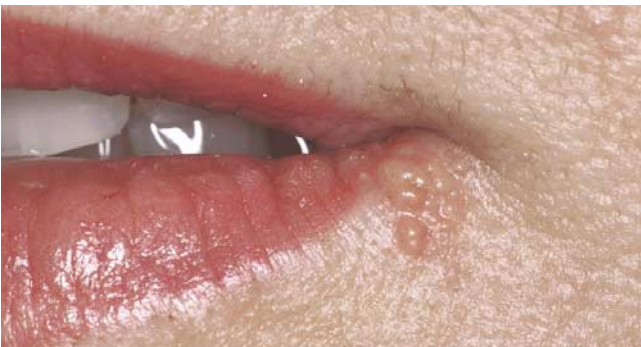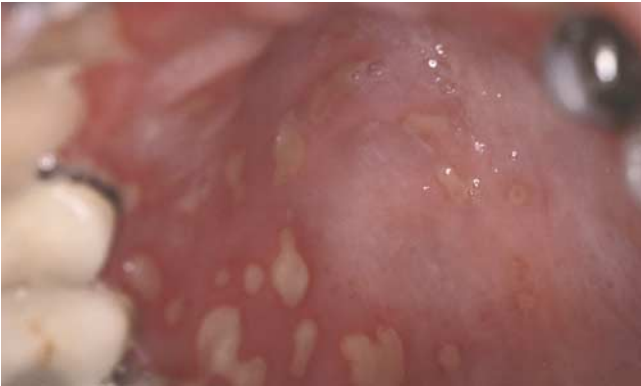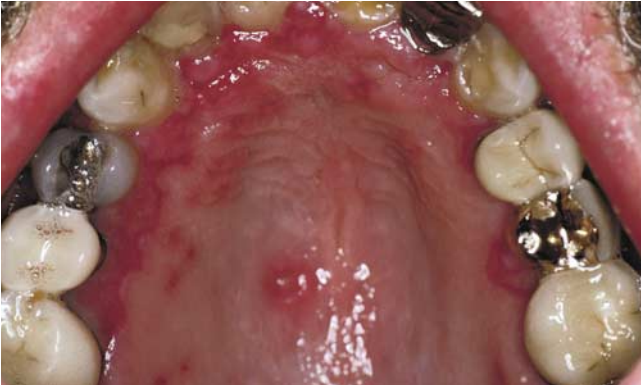- Erythema multiforme
- Herpes zoster (shingles)
- Herpangina
- Hand-foot-and-mouth disease

Treatment

- Acyclovir or valacyclovir early in prodrome
- Supportive
- Acyclovir may be used for prophylaxis for seropositive transplant patients
- Ganciclovir may be used for human immunodeficiency virus (HIV)-positive patients, especially those co-infected with cytomegalovirus.
- For recurrent herpes labialis, see “Therapeutics” section.

Prognosis

- Excellent
- Healing without scarring within 10 to 14 days
- Protracted healing in HIV-positive patients



Stevens-Johnson Syndrome

Etiology

- A complex mucocutaneous disease affecting two or more mucosal sites simultaneously
- Most common trigger: antecedent recurrent herpes simplex infection
- Infection with *Mycoplasma* also may serve as a trigger.
- Medications may serve as initiators in some cases.
- Sometimes referred to as “erythema multiforme major”

Clinical Presentation

- Labial vermilion and anterior portion of oral cavity usually affected initially
- Early phase is macular followed by erosion, sloughing, and painful ulceration
- Lip ulcers appear crusted and hemorrhagic.
- Pseudomembrane; foul-smelling presentation as bacterial colonization supervenes
- Posterior oral cavity and oropharyngeal involvement leads to odynophagia, sialorrhea, drooling
- Eye (conjunctival) involvement may occur.
- Genital involvement may occur.
- Cutaneous involvement may become bullous.
- Iris or target lesions are characteristic on skin.

Microscopic Findings

- Subepithelial separation with basal cell liquefaction
- Intraepithelial neutrophils
- Epithelial and connective tissue edema
- Perivascular lymphocytic infiltrate

Diagnosis

- Usually made on clinical grounds
- Histopathology is not diagnostic.

Differential Diagnosis

- Pemphigus vulgaris
- Paraneoplastic pemphigus
- Mucous membrane (cicatricial) pemphigoid

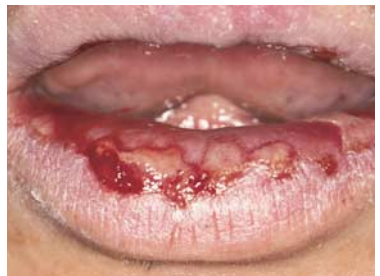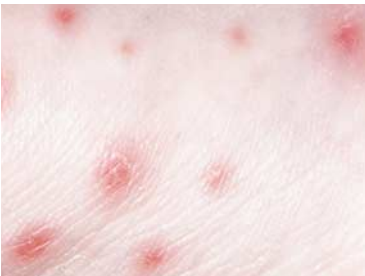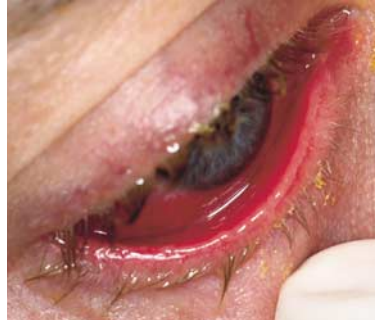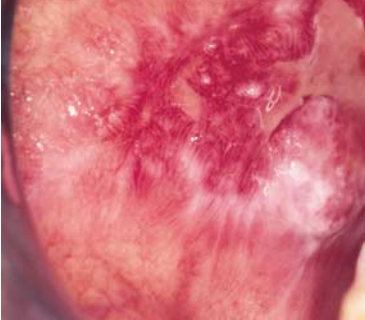
- Bullous pemphigoid
- Acute herpetic gingivostomatitis
- Stomatitis medicamentosa

Treatment

- Hydration and local symptomatic measures
- Topical compounded oral rinses
- Systemic corticosteroid use controversial
- Recurrent, virally associated cases may be reduced in frequency with use of daily, low-dose antiviral prophylactic therapy (acyclovir, famciclovir, valacyclovir).
- May require admission to hospital burn unit

Prognosis

- Good; self-limiting usually
- Recurrences not uncommon



Varicella and Herpes Zoster

Etiology

- Primary and recurrent forms due to varicella-zoster virus (VZV)
- Primary VZV (chickenpox): a childhood exanthem
- Secondary (recurrent) VZV (herpes zoster/shingles) infection: most common in elderly or immunocompromised adults

Clinical Presentation

- Varicella (chickenpox)
 - Fever, headache, malaise, and pharyngitis with a 2-week incubation
 - Skin with widespread vesicular eruption
 - Oral mucosa with short-lived vesicles that rupture forming shallow, defined ulcers
- Herpes zoster (shingles)
 - *Unilateral*, dermatomal, grouped vesicular eruption of skin and/or oral mucosa
 - Vesicles may coalesce prior to ulceration and crusting.
 - Lesions are painful.
 - Prodromal symptoms along affected dermatome may occur.
 - Pain, paresthesia, burning, tingling
 - Postherpetic pain may be severe.

Diagnosis

- Clinical appearance and symptoms
- Cytologic smear with cytopathic effect present (multinucleated giant cells)
- Viral culture or PCR examination of blister fluid or scraping from base of erosion
- Serologic evaluation of VZV antibody
- Biopsy with direct fluorescent examination using fluorescein-labeled VZV antibody

Differential Diagnosis

- Primary herpes simplex/acute herpetic gingivostomatitis
- Recurrent intraoral herpes simplex
- Pemphigus vulgaris
- Mucous membrane (cicatricial) pemphigoid

Treatment

- Symptomatic management in primary infection
- Antiviral drugs (especially acyclovir) in immunocompromised patients or patients with extensive disease
- Systemic corticosteroids may be used to help control/prevent postherpetic neuralgia.
- Pain control to prevent “CNS imprinting”

Prognosis

- Generally good
- Recurrences more likely in immunosuppressed patients

